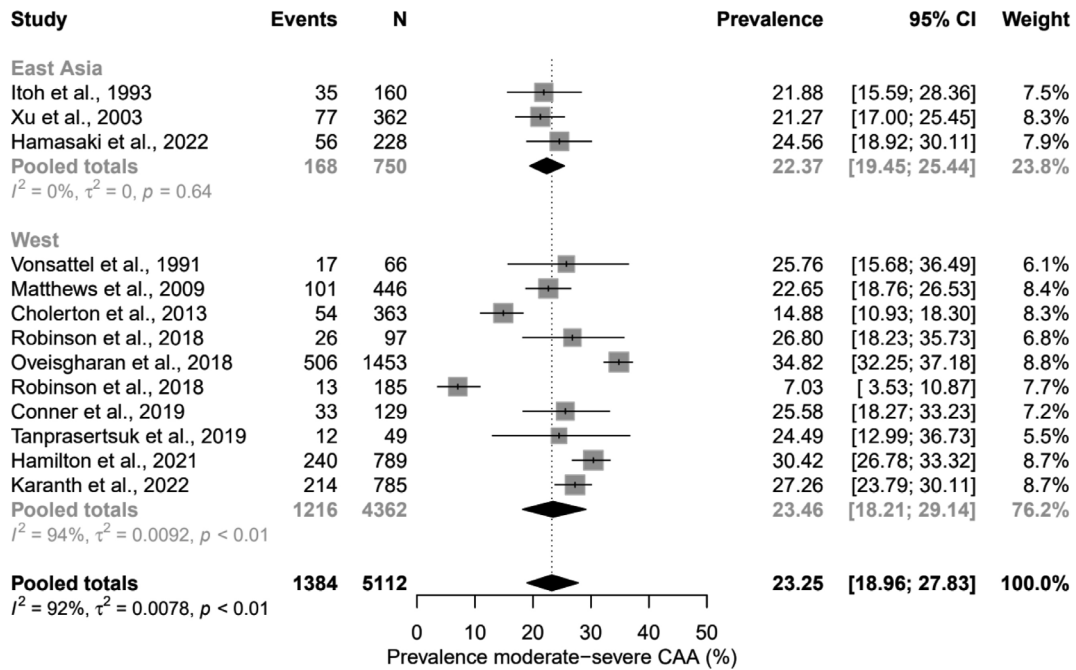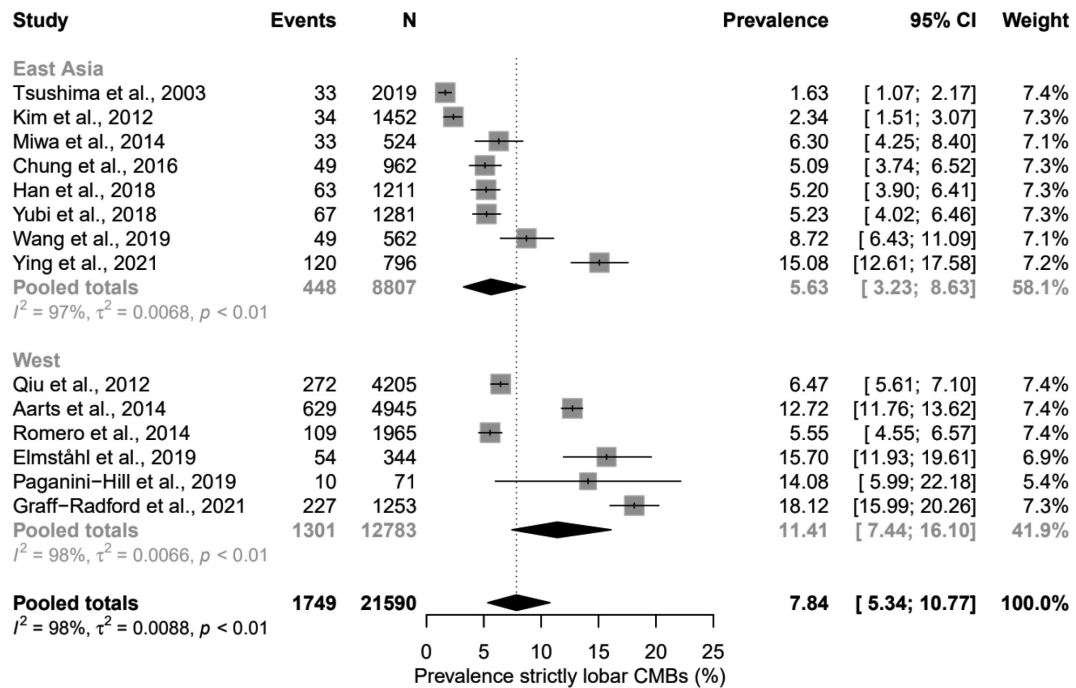


**Supplementary Figure 1.** Forest plots showing the prevalence of moderate-to-severe CAA pathology in the East-Asian and Western general populations. CAA, cerebral amyloid angiopathy; CI, confidence interval.



**Supplementary Figure 2.** Forest plots showing the prevalence of strictly lobar CMBs in the East-Asian and Western general populations. CMBs, cerebral microbleeds; CI, confidence interval.