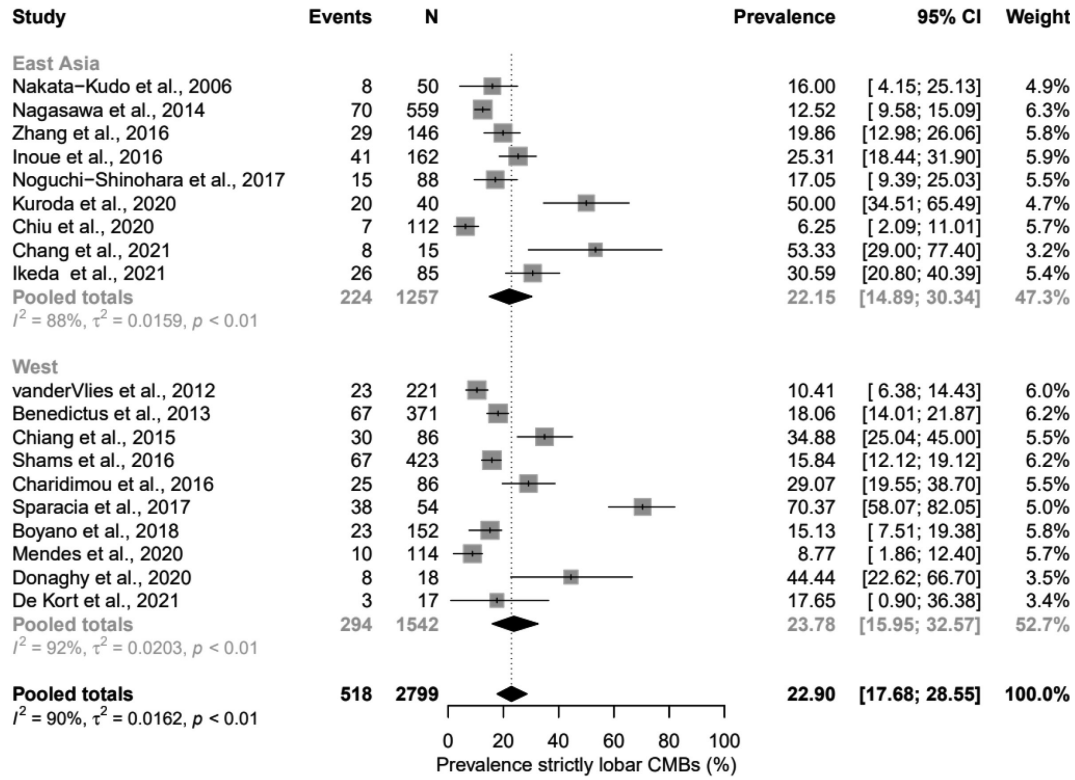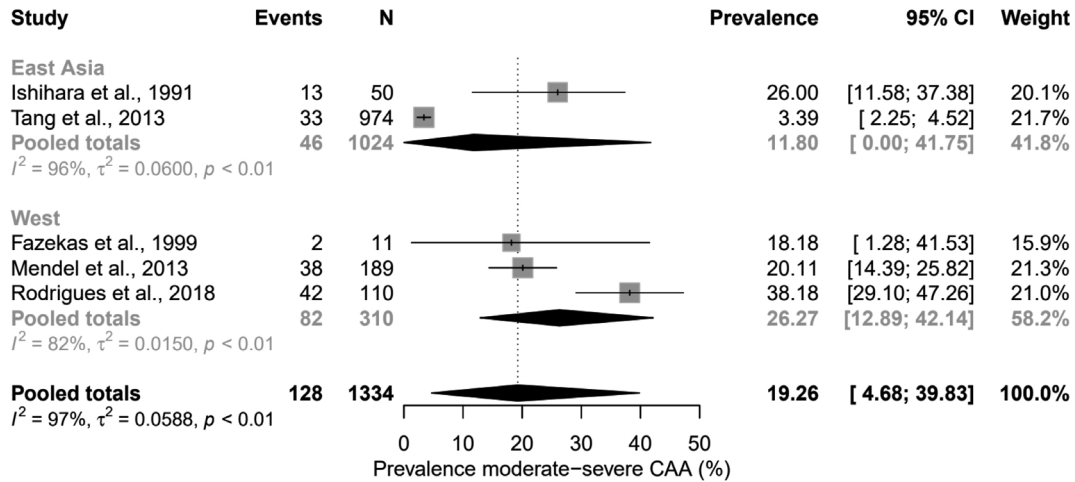


Supplementary Figure 6. Forest plots showing the prevalence of strictly lobar CMBs in East-Asian and Western patients with Alzheimer's disease. CMBs, cerebral microbleeds; CI, confidence interval.



Supplementary Figure 7. Forest plots showing the prevalence of moderate-to-severe CAA pathology in East-Asian and Western patients with ICH. CAA, cerebral amyloid angiopathy; ICH, intracerebral hemorrhage; CI, confidence interval.